

**Mechanochemical ablation in patients with chronic venous disease: A prospective multicenter report**

M Bishawi, R Bernstein, M Boter, D Draughn, CF Gould, C Hamilton and J Koziarski

*Phlebology* published online 2 July 2013

DOI: 10.1177/0268355513495830

The online version of this article can be found at:

<http://phl.sagepub.com/content/early/2013/07/02/0268355513495830>

Published by:



<http://www.sagepublications.com>

On behalf of:

American College of Phlebology



The Australasian College of Phlebology  
The European Venous Forum



The Venous Forum of The Royal Society of Medicine  
The Benelux Society of Phlebology



**Additional services and information for *Phlebology* can be found at:**

**Email Alerts:** <http://phl.sagepub.com/cgi/alerts>

**Subscriptions:** <http://phl.sagepub.com/subscriptions>

**Reprints:** <http://www.sagepub.com/journalsReprints.nav>

**Permissions:** <http://www.sagepub.com/journalsPermissions.nav>

>> **OnlineFirst Version of Record** - Jul 2, 2013

**What is This?**

# Mechanochemical ablation in patients with chronic venous disease: A prospective multicenter report

M Bishawi<sup>1</sup>, R Bernstein<sup>2</sup>, M Boter<sup>3</sup>, D Draughn<sup>4</sup>, CF Gould<sup>5</sup>, C Hamilton<sup>6</sup> and J Koziarski<sup>7</sup>

Phlebology  
0(0) 1–4  
© The Author(s) 2013  
Reprints and permissions:  
sagepub.co.uk/journalsPermissions.nav  
DOI: 10.1177/0268355513495830  
phl.sagepub.com  


## Abstract

**Background:** There are several endovenous methods to ablate the saphenous vein, all of which require tumescent anesthesia. This report was designed to evaluate the efficacy of a tumescent-free technique using mechanochemical ablation (MOCA).

**Methods:** This was a prospective observational multicenter report on the efficacy of MOCA in selected patients with lower extremity chronic venous disease. Demographic information, clinical and procedural data were collected on a customized database. The distribution and extent of venous reflux and the closure rate of the treated veins were assessed with duplex ultrasound. Pain was evaluated during the procedure and postoperatively using an analog scale. The presence and severity of complications were recorded. Patient improvement was assessed by clinical-etiology-anatomy-pathophysiology (CEAP) class and venous clinical severity score (VCSS).

**Results:** There were 126 patients that were included at baseline, 81% females, with a mean age of  $65.5 \pm 14$  years. The average BMI was  $30.5 \pm 6$ . The mean diameter of the great saphenous vein in the upper thigh was 7.3 mm and the mean treatment length was 38 cm. Adjunctive treatment of the varicosities was performed in 11% of patients during the procedure. Closure rates were 100% at one week, 98% at three months, and 94% at six months. Post-procedure complications included hematoma 1%, ecchymosis 9%, and thrombophlebitis 10%. There were no cases of venous thromboembolism. There was significant improvement in VCSS ( $p < 0.001$ ) for all time intervals.

**Conclusion:** MOCA of the saphenous veins has the advantage of endovenous ablation without tumescent anesthesia, making it an almost pain-free procedure. High occlusion rates with significant clinical improvement can be achieved with this method at short term.

## Keywords

Venous disease, varicose veins

## Introduction

Endovenous thermal procedures require the use of tumescent anesthesia which is associated with peri-procedural pain. Furthermore, most patients have post-procedural pain and ecchymosis. While ultrasound guided foam sclerotherapy represents a treatment option without the need of tumescent anesthesia, it usually requires multiple treatment sessions with results inferior to endothermal ablation.<sup>1,2</sup>

In an effort to eliminate the need for tumescent anesthesia, while still maintaining the excellent clinical results of endovenous thermal ablation, the ClariVein device (ClariVein, Madison, CT, USA) was introduced under the principal of mechanochemical treatment of

saphenous vein incompetence.<sup>3</sup> Available data in the literature come from single center studies of six weeks

<sup>1</sup>SUNY at Stony Brook, Department of Surgery, Stony Brook, NY, USA

<sup>2</sup>The Advanced Vein Treatment Center, Las Vegas, NV, USA

<sup>3</sup>Modern Vein and Laser Center, Brooklyn, NY, USA

<sup>4</sup>Vein Specialists of the Carolinas, Charlotte, NC, USA

<sup>5</sup>Teh Richmond Vein Center, Richmond, VA, USA

<sup>6</sup>Hamilton Vein Center, Houston, TX, USA

<sup>7</sup>Family Surgical and Vein Care, Battle Creek, MI, USA

This article was presented at the American College of Phlebology, Hollywood, FL, 2012.

## Corresponding author:

Muath Bishawi, Department of Surgery, T19-04 Health Sciences Center, Stony Brook, NY 11794-8191, USA.

Email: Muath.bishawi@stonybrookmedicine.edu

to one year follow-up. The aim of this post-market survey was to evaluate the safety, efficacy, and clinical outcomes of the ClariVein device on the treatment of the saphenous vein at six months post-procedure in multiple community centers.

## Methods

Data were prospectively collected from six vein centers using an electronic database. Demographic and clinical information were obtained at the baseline visit. The distribution and extent of venous reflux, the vein diameter, and closure rate were documented with duplex ultrasound. Procedural data included length of vein treated, volume of sclerosant used, and level of pain. The latter was evaluated during the procedure and postoperatively using a pain analog scale. Presence or absence of ecchymosis was recorded, along with any other procedural complications. Patients were followed with physical examination and duplex ultrasound at one week, three months, and six months. CEAP and VCSS scores were obtained at baseline and during follow-up.

## Patient selection

Symptomatic patients of CEAP Class 2 or higher requiring treatment of the great saphenous vein (GSV) were included. The diameter of GSV was measured at 2 cm below the sapheno-femoral junction (SFJ), mid-thigh, and distal thigh. Only veins with >4 mm and <12 mm in diameter were included. Measurements were performed in the standing position. Patients with small saphenous and accessory vein reflux, non-saphenous vein reflux, acute deep or superficial vein thrombosis, deep vein obstruction, previous venous intervention, significant peripheral arterial disease, and limb infection were excluded. Patients underwent pre-procedural conservative therapy with gradient elastic compression stockings. All the procedures were done in an outpatient office setting.

## Procedural details

Mechanochemical ablation (MOCA) of the saphenous veins has been described in detail.<sup>4</sup> Briefly, using local anesthesia and ultrasound guidance access of the GSV was obtained with a micro-puncture kit. Through a 4 or 5F micro-puncture sheath, the ClariVein catheter was advanced followed by the dispersion wire which was positioned 2 cm below the saphenofemoral junction. After initiating the drive unit causing spasm of the vein, sclerosant was infused. Concentration, type, and volume of sclerosant and pullback speed were up to the discretion of each center. The

procedural details of treatment from each center were recorded.

## Statistical analysis

The clinical characteristics of the patients were analyzed with descriptive statistics. Mean with standard deviations was reported for continuous variables, and percentages for categorical variables. The CEAP and VCSS class change after treatment were compared with Wilcoxon signed-rank test as a more conservative approach. SPSS 20 (SPSS Inc., Chicago, IL, USA) was used.

## Results

A total of 126 patients were enrolled at baseline. The average age was 65.5 years and 81% were females (Table 1). Medicare was the primary insurance used (76% of patients). The distribution of CEAP was 48% with Class 2 and 3, 48% with skin damage (C4–C6), and only 4% with Class 1. Hypertension had a prevalence of 43% in the enrolled patients followed by hyperlipidemia in 21%. The mean diameter  $\pm$  SD of the GSV in the upper thigh was  $7.3 \pm 2.6$  mm and the mean  $\pm$  SD treatment length was  $38 \pm 14$  cm. Catheter length used was 45 cm in 32% of the patients and 65 cm in 68% of the patients. The sclerosant used was sodium tetradecyl sulfate (STS) in 84% of the patients and polidocanol in 16% of the patients. Adjunctive treatment of the varicosities was performed in only 11% of the patients at the time of the procedure (mini-phlebectomy in 7% and sclerotherapy in 4%). Technical success was achieved in all patients. There were no intra-procedural complications and 98% of patients were sent home with compression stockings. Follow-up was available for 125

**Table 1.** Demographics and clinical characteristics of the patients.

Variable	Value, n (%)
Age	65.46 $\pm$ 14
Female sex	102 (81)
BMI	30.5 $\pm$ 6
Medicare	96 (76)
Hypertension	55 (44)
Hyperlipidemia	27 (21)
Coronary artery disease	8 (6)
Diabetes	15 (12)
History of DVT/PE	9 (7)
Peripheral vascular disease	1 (1)
Coumadin/Plavix use	28 (22)

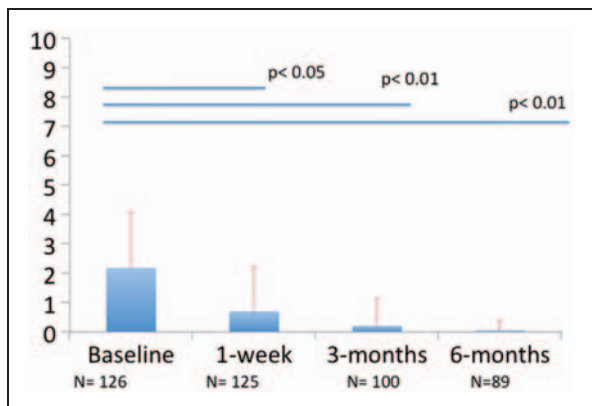
patients in one week. Thrombophlebitis was present in 10%, ecchymosis in 9%, and hematoma in 1%. At one week, 49% of treated patients continue to have residual varicose veins. Complete three- and six-month data were available for 100 and 89 patients, respectively. The mean pain score at the time of the procedure was 2 and >1 at one week (Figure 1). There was significant reduction in the CEAP and VCSS class as shown in Figures 2 and 3. The closure rate over time is displayed in Figure 4 and was 94% at six months. There were five recanalizations, two of which were complete and three segmental.

**Discussion**

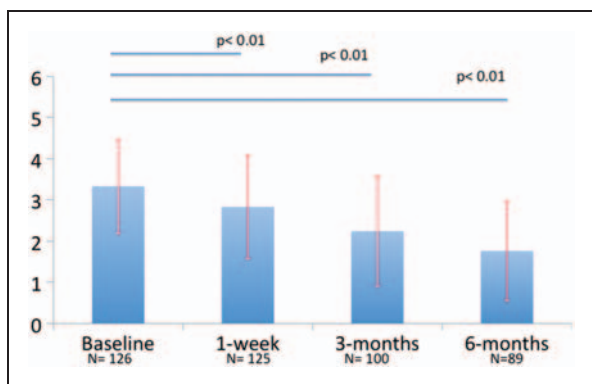
This represents the first multicenter data from community vein centers on the use of MOCA in patients with chronic venous disease. The population in this report was significantly older and the BMI was higher compared to published studies using endothermal techniques. The occlusion rate at three and six months was comparable to the endothermal procedures in

spite of the older population and the higher BMI.<sup>5,6</sup> The two complete recanalizations occurred early in the study but there was not apparent explanation. The three segmental recanalizations were asymptomatic. Similar findings in terms of complete and partial recanalization have been reported with endothermal techniques. The GSV diameter was comparable to other studies despite having an upper limit of 12 mm. This was probably due to the older population having a longer disease duration and more advanced disease. The diameter of the vein had no impact on the recanalization. Similar results for MOCA have been shown in recent or current studies for both the GSV and SSV.<sup>3,4,7,8</sup> The closure rate and clinical outcome with MOCA remained comparable at two-year follow-up in a recent study.<sup>9</sup>

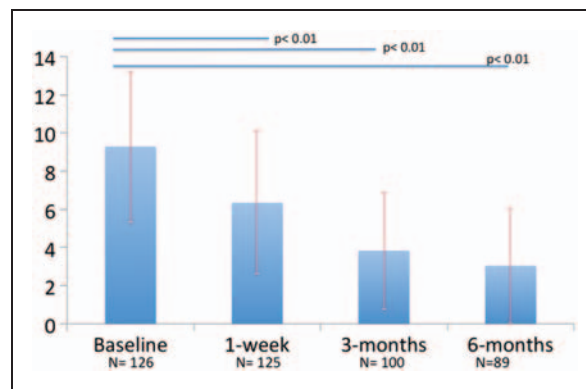
The technical success was excellent as patients with previous thrombosis were excluded. Negotiating the catheter in veins that have no previous thrombosis is fairly easy as significant varicosities in the GSV trunk



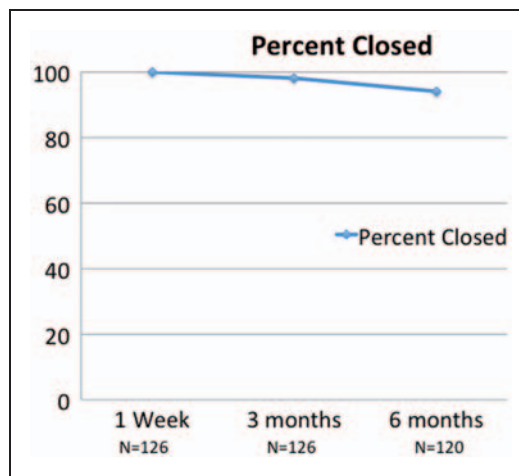
**Figure 1.** Visual analog pain scores (0–10) over time.



**Figure 2.** CEAP class at baseline and during follow-up.



**Figure 3.** VCSS at baseline and during follow-up.



**Figure 4.** Saphenous vein closure rate at one week, three months, and six months.

occurs in about 3% of patients presenting with varicose veins with a mean length of 4 cm.<sup>10</sup> The pain during the procedure was minimal with a pain score of 2 or less making the MOCA procedure very attractive for outpatient use. The endothermal techniques are bound to use tumescence anesthesia, therefore increasing the level of pain during the procedure. Due to thermal injury, the postoperative pain in the endothermal techniques is more than the MOCA as was also recently shown in a prospective study comparing RFA with MOCA.<sup>7</sup>

There was significant improvement after treatment as shown by the marked reduction in the CEAP class and the VCSS in spite of not treating the varicosities in the majority of the patients at the same time. Secondary interventions were performed over time when clinically indicated. The CEAP had not the apparent high drop seen in other studies as 48% of the patients in our cohort had skin damage which was significantly higher than any other study. Patients with skin damage may improve their discoloration but this does not disappear in the majority of the cases and, therefore, further class reduction in such patients is not achieved. However, the dramatic effect of treatment was best reflected on the marked reduction in the VCSS.

Clearly, the current report has several limitations as there is no control group and historical data from other studies are used for comparison. However, it demonstrated that the MOCA technique could be used in the community setting producing very good early term results. It is important to demonstrate the efficacy of this method at long term in randomized studies that are appropriately powered.

### Funding

This research received no specific grant from any funding agency in the public, commercial, or not-for-profit sectors.

### Conflict of interest

MB confirms no conflict of interest. RB received a grant from Vascular Insights for survey expenses. M Boter received a grant from Vascular Insights for survey expenses. DD received a grant from Vascular Insights for survey expenses.

CFG received a grant from Vascular Insights for survey expenses. CH received a grant from Vascular Insights for survey expenses. JK received a grant from Vascular Insights for survey expenses.

### References

1. Hamel Desnos C, Ouvry P, Benigni JP, et al. Comparison of 1% and 3% polidocanol foam in ultrasound guided sclerotherapy of the great saphenous vein: A randomized double blind trial with two year follow-up. The 3/1 study. *Eur J Vasc Surg* 2007; 34: 723–729.
2. Ceulen RPM, Bullens-Goessens Y, Pi-Van de V, et al. Outcomes and side effects of duplex guided sclerotherapy in the treatment of great saphenous veins with 1% versus 3% polidocanol foam: Results of a randomized controlled trial with one year follow up. *Dermatol Surg* 2007; 33: 276–281.
3. van Eekeren RR, Boersma D, Elias S, et al. Endovenous mechanochemical ablation of great saphenous vein incompetence using the ClariVein device: A safety study. *J Endovasc Ther* 2011; 18: 328–334.
4. Elias S and Raines JK. Mechanochemical tumescenceless endovenous ablation: Final results of the initial clinical trial. *Phlebology* 2012; 27: 67–72.
5. Almeida JI, Kaufman J, Gockeritz O, et al. Radiofrequency endovenous closureFAST versus laser ablation for the treatment of great saphenous reflux: A multicenter single-blinded randomized study (RECOVERY). *J Vasc Interv Radiol* 2009; 20: 752–759.
6. Proebstle TM, Vago B, Alm J, et al. Treatment of the incompetent great saphenous vein by endovenous radiofrequency powered segmental thermal ablation: First clinical experience. *J Vasc Surg* 2008; 47: 151–156.
7. van Eekeren RR, Boersma D, Konijn V, et al. Postoperative pain and early quality of life after radiofrequency ablation and mechanochemical endovenous ablation of incompetent great saphenous veins. *J Vasc Surg* 2013; 57: 445–450.
8. Boersma D, van Eekeren RR, Werson DA, et al. Mechanochemical endovenous ablation of small saphenous vein insufficiency using the ClariVein® device: One-year results of a prospective series. *Vasc Endovasc Surg* 2013; 45: 299–303.
9. Elias S, Lam YL and Wittens CH. Mechanochemical ablation: Status and results. *Phlebology* 2013; 28: 10–14.
10. Labropoulos N, Kokkosis AA, Spentzouris G, et al. The distribution and significance of varicosities in the saphenous trunks. *J Vasc Surg* 2010; 51: 96–103.